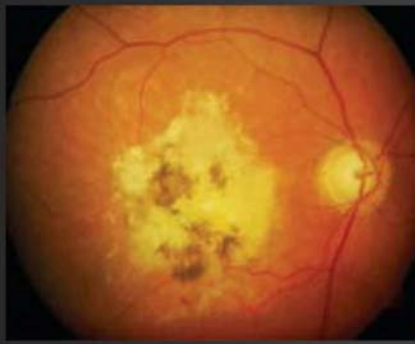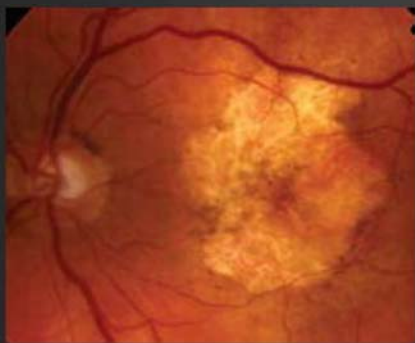


Advanced AMD

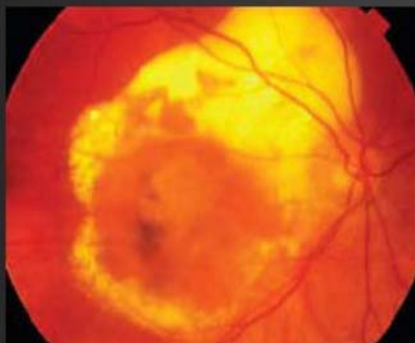Refer if fulfils guidelines on form



Disciform Scar: Extensive subretinal fibrosis and pigment change at the macula. This shows advanced disease.



Geographic atrophy: Another form of advanced AMD (Dry) showing extensive retinal atrophy / thinning at the macula.



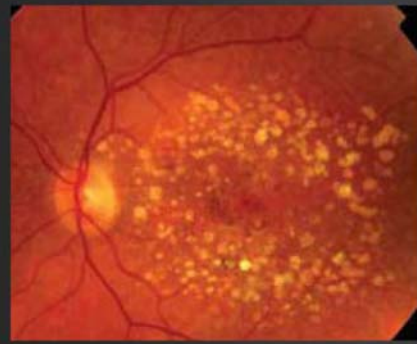
Advanced wet AMD - central macular elevation with/without subretinal fluid, hard exudate and some fibrosis.

If best corrected visual acuity is worse than 6/96, these patients may require a hospital assessment on a non-urgent basis.

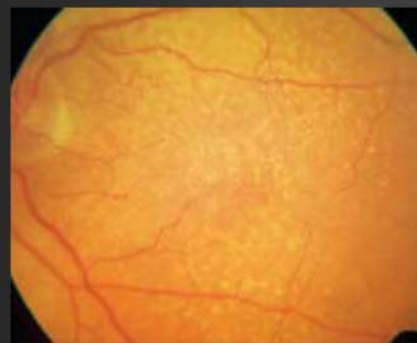They may benefit from LVA assessment, visual impairment counselling and/or registration.

Drusen

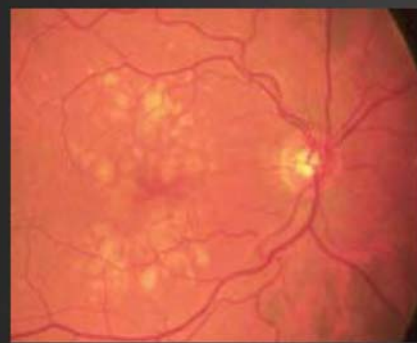Refer only if fulfils guidelines on form



Multiple drusen and pigment change.



Multiple fine hard drusen.



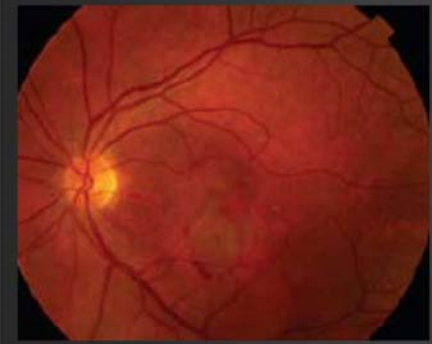
Large soft drusen.

These appearances are consistent with Age Related Maculopathy (ARM). Patients with drusen commonly notice distortion when shown an Amsler grid. This is less significant than spontaneously reported visual distortion.

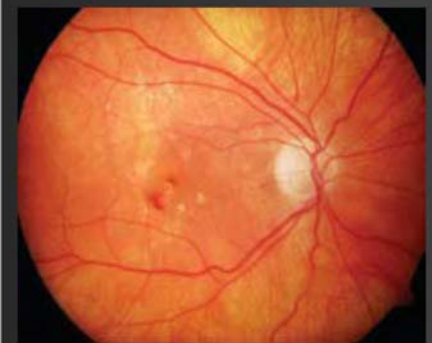Only refer if patient has noticed sudden onset of distortion or blurring of central vision. If the patient smokes they should be encouraged to give up as smoking has been shown to be a risk factor in the development of AMD. These patients may benefit from ocular nutritional supplements.

Wet AMD

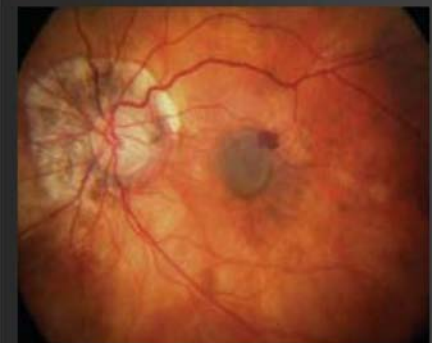Refer if fulfils guidelines on form



Subretinal haemorrhage and subretinal fluid suggest choroidal neovascularisation. **This patient requires urgent referral and assessment.**



Intraretinal haemorrhage centrally and exudates deposition superiorly. There may be associated subtle subretinal fluid or thickening. The presence of exudates is an important sign of leakage from choroidal neovascularisation. **Refer urgently.**



Small areas of intra / sub retinal haemorrhage amongst the drusen suggest choroidal neovascularisation. **This patient requires urgent referral and assessment.**

Blood, retinal swelling and exudates deposition at the macula suggest wet AMD requiring urgent referral.

Please refer according to local protocols or use the attached form and fax to the appropriate consultant.

WET AMD RAPID ACCESS REFERRAL FORM

Name of Consultant:

Hospital Contact Details:

PATIENT DETAILS

NAME: _____ DOB: _____ HOSPITAL NO: _____
ADDRESS: _____ (If known)
CONTACT TEL NOS: _____

GP NAME: _____ GP SURGERY: _____

OPTOMETRIST DETAILS:

NAME: _____ PRACTICE: _____
GOC NO: _____ ADDRESS: _____
TEL: _____ FAX: _____
AFFECTED EYE: RIGHT: LEFT:
PAST HISTORY IN EITHER EYE
PREVIOUS AMD RIGHT: LEFT:
MYOPIA RIGHT: LEFT:
OTHER RIGHT: LEFT:

REFERRAL GUIDELINES

PRESENTING SYMPTOMS IN AFFECTED EYE (one answer must be yes, please mark the correct box with an 'X')

Duration of visual loss:

- | | | |
|---|------------------------------|-----------------------------|
| 1. Visual Loss | YES <input type="checkbox"/> | NO <input type="checkbox"/> |
| 2. Spontaneously reported distortion | YES <input type="checkbox"/> | NO <input type="checkbox"/> |
| 3. Onset of scotoma (or blurred spot) in central vision | YES <input type="checkbox"/> | NO <input type="checkbox"/> |

FINDINGS Best corrected VA (must be 6/96 or better in affected eye)

- | | | |
|--------------------------------|--|---|
| 1. Distance VA | RIGHT: <input type="checkbox"/> / <input type="checkbox"/> | LEFT: <input type="checkbox"/> / <input type="checkbox"/> |
| 2. Near VA | RIGHT: <input type="checkbox"/> | LEFT: <input type="checkbox"/> |
| 3. Macular drusen (either eye) | RIGHT: <input type="checkbox"/> | LEFT: <input type="checkbox"/> |

In the affected eye ONLY, presence of:

- | | | |
|--|---------------------------------|--------------------------------|
| 4. Macular haemorrhage (preretinal, retinal, subretinal) | RIGHT: <input type="checkbox"/> | LEFT: <input type="checkbox"/> |
| 5. Subretinal fluid | RIGHT: <input type="checkbox"/> | LEFT: <input type="checkbox"/> |
| 6. Exudate | RIGHT: <input type="checkbox"/> | LEFT: <input type="checkbox"/> |

Comments

ADDITIONAL COMMENTS:

Fax Form Received and refer informed YES NO

